



STONES/ENDOUROLOGY
ORIGINAL ARTICLE

Extending indications of micropercutaneous nephrolithotomy: It is not just about cracking stones



Arvind P. Ganpule, Jaspreet Singh Chhabra, S.B. Sudharsan, Ankush Jairath*, Mohankumar Vijaykumar, Ravindra Sabnis, Mahesh R. Desai

Department of Urology, Muljibhai Patel Urological Hospital, Nadiad, Gujarat, India

Received 25 September 2016, Received in revised form 2 November 2016, Accepted 27 November 2016
Available online 7 January 2017

KEYWORDS

Micropercutaneous nephrolithotomy (microperc); VUR; Posterior urethral valve (PUV); Calculi

ABBREVIATIONS

KUB, plain abdominal radiograph of the kidneys, ureters and bladder; PCNL, percutaneous nephrolithotomy; PUV, posterior urethral valve; MP, micropercuta-

Abstract Objective: To describe our experience and results of using the MicroPerc™ micropercutaneous nephrolithotomy armamentarium (PolyDiagnost, Germany) for unusual indications unexplored using this modality.

Patients and methods: We used the MicroPerc™ system for stone clearance in three ureteric calculi, two bladder calculi, one case of urethral calculus, for antegrade biopsy in a case of upper tract urothelial carcinoma, for Deflux® (dextranomer/hyaluronic copolymer, Salix Pharmaceuticals, Uppsala, Sweden) injection in three cases of vesico-ureteric reflux (VUR), and three cases of posterior urethral valve (PUV) fulgurations. A 4.85-F ‘All-Seeing Needle®’ (PolyDiagnost) was used in most of the cases. An 8-F mini-micro sheath was used where stability was deemed necessary. Clinical data were collected in a dedicated database. Intraoperative variables, post-operative complications, and outcomes were assessed.

Results: All patients were successfully treated with complete stone clearance at 1 month with no residual fragments. The antegrade biopsy confirmed a high-grade papillary neoplasm. There were no technical difficulties with injection of Deflux or PUV fulgurations. Follow-up at 1 year revealed no stone recurrence, resolved reflux in all three cases, and all the children that had had PUVs were voiding well. The small sample and retrospective nature of the analysis are the limitations of this study.

Conclusion: MicroPerc™, besides its usual use for minimally invasive percutaneous nephrolithotomy, can also be feasibly used for ureteric, bladder and urethral

* Corresponding author. Fax: +91 268 2520248/2520331.

E-mail address: ankushjairath@rediffmail.com (A. Jairath).

Peer review under responsibility of Arab Association of Urology.



Production and hosting by Elsevier

neous nephrolithotomy/MicroPerc; URS, ureterorenoscopy; YAG, yttrium-aluminium-garnet; VCUG, voiding cystourethrography

stones, and for treating non-calculus diseases such as PUVs and VUR. True to its name, it may be an 'All-Seeing Needle' in reality with much more to offer and harvest from.

© 2016 Arab Association of Urology. Production and hosting by Elsevier B.V. This is an open access article under the CC BY-NC-ND license (<http://creativecommons.org/licenses/by-nc-nd/4.0/>).

Introduction

The past few decades have seen a paradigm shift in the management of renal stones, with percutaneous nephrolithotomy (PCNL) becoming the established 'gold standard' for the management of large renal calculi [1]. Although associated with high clearance rates, it carries with it a distinct set of morbidities. Ever since the latter were realised, efforts have been made to address these issues. This led to the notion of miniaturisation, with better optics and the development of flexible instruments. The modifications in PCNL range from the mini-PCNL (miniperc) to the ultra-microPCNL (ultra-miniperc) to the most miniaturised the microPCNL (microperc). The 'All-Seeing Needle®' (PolyDiagnost, Hallbergmoos, Germany) introduced by Bader et al. [2], has several unique properties, it is slender (4.85 F), relatively flexible, and has provision for connecting a three-way adapter. The latter can admit an irrigation source, energy source in the form of a laser fibre, and a flexible telescope. These very properties lend versatility to the microperc (MP) armamentarium.

Recently there has been an increase in publications on MP and its armamentarium, reporting the feasibility and safety of MP in managing renal calculi, both in adults and the paediatric population alike [3,4]. However, the data on the use of MP in other facets of urological surgery are scarce. In the present study, we present our experience and results of using the MicroPerc® micropercutaneous nephrolithotomy armamentarium (PolyDiagnost) for uncommon indications and indications unexplored to date using this technique.

Patients and methods

For application of MP in the clinical setting an Institutional Review Board approval was sought. We have been performing MP in our institute since 2011 [5]. The technique was initially applied to cases of renal calculi in orthotopically positioned kidneys bearing small calculi, i.e. primarily in management of stone disease. Thereafter, with increasing experience and promising outcomes, we decided to extend the scope of the technique to other clinical scenarios. We studied the use of the MP system in three cases of lower ureteric calculus, two cases of vesical calculi, one case of urethral calculus, three cases of Deflux® (dextranomer/hyaluronic copoly-

mer, Salix Pharmaceuticals, Uppsala, Sweden) injection for VUR, three cases of posterior urethral valve (PUV) fulguration, and for procuring a biopsy for a case of an upper tract mass lesion.

The preoperative evaluation included: history and a thorough clinical examination; renal function tests; urine routine examination; urine culture; plain abdominal radiograph of the kidneys, ureters and bladder (KUB); and a CT IVU for stone diseases. As per institutional policy, children presenting with recurrent UTIs and identified with Grade III–IV VUR on voiding cystourethrography (VCUG) were started on antimicrobial prophylaxis. Three children presenting with breakthrough infections despite prophylaxis were identified for Deflux injections. Three children identified with PUVs on VCUG were enrolled for fulguration using the MP setup. A case of haematuria upon evaluation with CT IVU was identified with a renal pelvic mass lesion. The patient required an antegrade biopsy that was attempted successfully using MP.

Surgical technique

The MP armamentarium (Fig. 1)

The workhorse of the MP setup comprises of the three part 4.85-F 'All-Seeing Needle', presented by Bader et al. [2]. After establishing the initial access the inner sharp bevelled needle housing the telescope is removed. A three-way connector is then attached to the proximal end. The three ends of the connector allow use of a 200 or 272 µm laser fibre, an irrigation connection, and a telescope through the other side port (Fig. 1). The highly flexible fibre-optic telescope contains 10,000 fibre-optic bundles and can be bent over itself without causing damage. Vision is controlled to the optimum level using an irrigation pump as required, which is controlled by a foot pedal by the operating surgeon. Although the telescope and irrigation sources, owing to their nature continued to be used, the laser fibre could be substituted for miniaturised accessories, depending upon the nature of procedure to be undertaken.

The other components comprise of 8-F mini-micro sheath (with obturator) that offers a more stable system, allowing easy manoeuvring from one calyx to other (as in mini-micro PCNL) and traversing the urethra for the transurethral procedures [Deflux injection, ureterorenoscopy (URS) and PUV fulguration]. Although not a

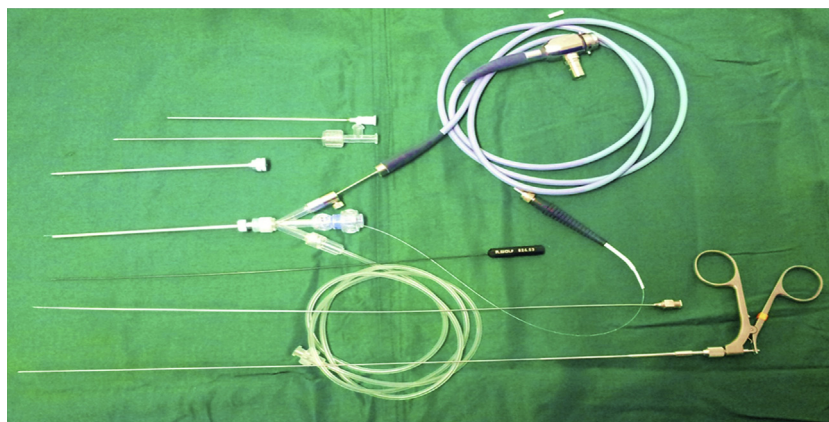


Fig. 1 The MP armamentarium.

part of the typical MP setup, the accessories we used comprised: 3-F forceps, Bugbee electrode, and Deflux needle.

Management of lower ureteric calculi

The mini-micro 8-F sheath with the three-way connector (bearing the camera, laser fibre, and irrigation attachments) was passed transurethraly into the ureter. The ureteric orifice could easily be negotiated without dilatation. The stone being in the lower ureter was easily identified and fragmented using the laser (0.8 J, 12 Hz settings). Complete clearance was achieved and a JJ stent was inserted at the end of the procedure as clinically indicated by an impacted stone or an unhealthy ureter.

Management of vesical/urethral calculi

The MP 4.85-F 'All-Seeing Needle' with three-way connector was passed transurethraly to the level of stone. The stone was visualised and fragmented with the laser (0.5 J, 10 Hz settings). Complete clearance was achieved.

Management of upper tract pelvic mass

A case of upper tract TCC was encountered and CT revealed a small right medial pelvic mass of 9 mm. A routine retrograde URS and biopsy was attempted, but could not be completed due to a high median lobe and non-dilating lower ureter. An antegrade biopsy was done using the MP system, visualising the mass and using 3-F cold cup biopsy forceps. The biopsy report confirmed a high-grade papillary neoplasm.

Deflux injection

After placing the child in lithotomy position under general anaesthesia, the 8-F mini-micro sheath with obturator was passed per urethraly and the obturator exchanged for the three-way connector bearing the components of the system. Cystoscopy was performed to localise the ureteric orifices. The camera and the irrigation system occupied the side whereas the Deflux metal

needle (3.7 F \times 23 G tip \times 350 mm) occupied the central channel. Deflux (2 mL) was injected to raise the mound at each of the ureteric orifices.

PUV fulguration

The 8-F mini-micro sheath was introduced into urethra with the three-way Touhy boursst adapter attached and the complete assembly of camera, irrigation tubing, and 200 μ m laser fibre. The introduction of the assembly is similar to any paediatric cystoscopic sheath. The PUVs were identified and fulguration completed with the laser. The adequacy of the fulguration was confirmed intraoperatively by observing the urinary stream on performing the Credé's manoeuvre with the patient under anaesthesia. A urethral catheter was placed after the procedure and was removed after 48 h and the children were discharged on day 2.

Postoperative course

Pain control was achieved using i.v. non-opioid analgesics, gradually substituted by oral analgesics from the first postoperative day. A single dose of preoperative antibiotic prophylaxis was given unless otherwise indicated. Oral intake was initiated 3–6 h after the procedure with clear liquids, gradually advancing to a normal diet.

Postoperative follow-up

Stone patients

Stone patients were assessed for clearance at 24–48 h after procedure with a KUB and ultrasonography. This was also carried out at 1, 3, 6, and 12 months follow-up. JJ stents, if placed, were removed at 1 month.

Upper tract urothelial malignancy

The patient was followed up for local and systemic recurrence with regular blood investigations and contrast CT of the abdomen and pelvis. At 24 months

follow-up, the patient was doing well without any disease relapse.

VUR

All children injected with Deflux were closely followed for symptoms of UTI, serum creatinine, and urine routine examination at 1, 3, 6, and 12 months follow-up, with a repeat VCUG at 3 months.

PUV

Patients were evaluated for symptoms and urinary flow was objectively analysed using uroflowmetry. A VCUG was performed at the 3-month follow-up showing complete ablation of the valves. Ultrasonography to confirm resolution of hydroureteronephrosis was also done at same time.

Data analysis

Demographic data, preoperative clinical information, and perioperative and follow-up variables were recorded and analysed. Stone clearance and the need for auxiliary procedures were analysed. VUR patients were closely monitored for persistence of reflux and breakthrough infections. PUV patients were assessed for a fall in serum creatinine and maintenance of good urinary flow. Complications were classified according to the Clavien–Dindo classification.

Results (Table 1)

We successfully treated three cases of lower ureteric calculus using 4.85-F sheath MP assembly. The mean (SD) stone size and density [Hounsfield units (HU)] were 8.6 (4) mm and 1240 HU. The mean haemoglobin drop was 0.4 g/dL. Stone clearance assessed by KUB and ultrasonography at day 1, and then at 1 and 3 months. There were no clinically insignificant fragments (<4 mm) in any of the cases. One patient required JJ-stent insertion and two had a fever (Clavien–Dindo Grade I).

Two patients with bladder calculi were treated with the MP system. The mean (SD) age and stone size were 18 years and 13.2 (4) mm. The mean (SD) operative time was 21 (2) min and the haemoglobin drop was 0.3 g/dL. All fragmentation was done using a holmium laser, with complete clearance on fluoroscopy at completion of the procedure.

We used the MP system in one patient with a prostatic urethral calculus. The 12-year-old boy presented with dysuria and was identified with a prostatic utricle with an 11-mm calculus in it. The operative time was 35 min and the stone was completely dusted with the laser (0.8 J, 12 Hz). The child developed fever (Clavien–Dindo Grade I) and was managed conservatively with antipyretics.

One patient with an upper tract TCC was included and CT revealed a small right medial pelvic mass of 9 mm. The biopsy report confirmed a high-grade papillary neoplasm. The patient subsequently underwent nephroureterectomy and the final pathology report identified a high-grade non-invasive urothelial carcinoma.

Deflux injection was done using the Optical needle in three patients. The mean (SD) age of the children was 5.2 (3) years and the operative time was 22 (4) min. After the procedure, all patients had a reduction in their grade of reflux (by one or two) and none of the patients had procedure-related complications or breakthrough infections at the 6-month follow-up. One child developed a protracted fever requiring antibiotics for 14 days (Clavien–Dindo Grade II).

Three cases of PUV were fulgurated using the ‘All-Seeing Needle’. The mean (SD) age of the children was 1.8 (0.7) years. In all children, the per urethral catheter was removed on postoperative day 1 and all children voided well after removal. The mean serum creatinine at the 1-month follow-up was 0.35 g/dL and none had any stream-related disturbances at the 12-month follow-up.

Discussion

At our centre, we have performed and reported stone clearance in two cases of pelvic ectopic kidneys [6]. We have also published on the feasibility of the use of MP in the paediatric population [7]. In the present study, we further extend the use of the MP armamentarium to less common indications.

Lower ureteric calculi

European guidelines identify URS as a first-line treatment, along with shockwave lithotripsy, in the management of ureteric and renal calculi in paediatric patients [1]. A factor of specific concern in the management of paediatric ureteric stones is the delicate narrow calibre ureter, warranting extreme care during negotiating and fragmenting of the stone [8]. The commonly used 7.5-F ureteroscope, apart from requiring dilatation of the ureteric orifice on occasion, is also associated with a significant length of scope shaft projecting out from the meatus and reaching up to the surgeon [9]. The self-dilating 4.5-F scope has a tapered tip with a 6.5-F body, particularly suited for distal or mid-ureteric stones; this has allowed intubation of smaller ureters without the need for dilatation [9]. An additional advantage of the 4.5-F scope is the drastically decreased need for ureteric dilatation to remove the stones successfully [10].

In our present patients, we dealt successfully with ureteric calculi using the MP assembly as described earlier. The tapered tip allowed for a self-dilating mechanism, allowing the negotiation of the ureteric orifice

Table 1 Indications treated with MP and their characteristics.

Variable	Micro-URS	Vesical calculus	Urethral calculus	Antegrade biopsy	Deflux injection	PUV fulguration
Number of patients (total 13)	3	2	1	1	3	3
Patient age, years, median (range)	28 (3–46)	18 (14–24)	12	67	5.2 (2–7)	1.8 (1–3)
Stone size, mm, mean (SD)	8.6 (4)	13.2 (4)	11	NA	NA	NA
Stone density, HU, mean (SD)	1240 (320)	1310 (210)	1280	NA	NA	NA
Location	Lower ureter	NA	Posterior urethra	Renal pelvis	NA	NA
Operative time, min, mean (SD)	36 (8)	21 (2)	35	16	22 (4)	18 (8)
Postoperative drainage	JJ stent (1 case)	Foley catheter	Foley catheter	0	Foley catheter	Foley catheter
Clavien–Dindo complications, <i>n</i>						
Grade I	2	0	1	0	1	1
Grade II	0	0	0	0	1	0
Grade III	0	0	0	0	0	0

NA, not applicable.

with ease without resorting to dilatation. The much smaller shaft length imparts easy manoeuvrability and improved ergonomics. This together with the provision for irrigation and holmium-yttrium-aluminium-garnet (Ho-YAG) laser fibre channels, allowed the successful fragmentation of the stones.

Vesical calculi

Akin to the other realms of urological surgery there has been a paradigm shift in the management of vesical calculi. The earlier trend of open cystolithotomy has seceded to contemporary minimally invasive endoscopic methods, such as transurethral and suprapubic interventions. Nevertheless, there are concerns associated with transurethral and suprapubic interventions [11,12]. The former is associated with increased incidence of urethral strictures and bladder neck injury. To the contrary, percutaneous suprapubic cystolithotomy bypasses the urethra, thereby avoiding urethral complications, but the tract dilatation associated with this approach may lead to intra-abdominal fluid leakage and ileus. MP may hold a unique place in such a scenario, as it retains the advantage of the suprapubic route, with the added benefit of single step access. Theoretically, this appears to be particularly appealing in paediatric population and cases of urethral stricture disease.

Piskin et al. [13], in their feasibility study of MP for bladder stones, treated two patients aged 5 and 72 years with stones of 15 and 12 mm, respectively; the total operative time of was 40 and 35 min, respectively, with catheterisation and hospital stay of 1 day, and no complications.

In another study by Bodakci et al. [14], the authors reported their experience with MP for managing vesical calculi in paediatric patients. Of the 12 patients with a mean age of 2.6 years and mean (range) stone size of

14 (7–32) mm and procedure time of 38.7 (15–65) min. The mean (range) hospital stay reported was 1.4 (0.5–4) days and the stone-free rate was 91.6% after one intervention, which increased to 100% after two sessions. One patient each had transient macroscopic haematuria, acute urinary retention, and in another patient a second session was required.

Urethral calculi

To the best of our knowledge, the present study is the first to report on the use of the MP system to treat a urethral calculus. Traditionally, urethral calculi are treated by pushing the stone into the bladder and fragmenting with the help of a laser or Lithoclast [15]. *In situ* fragmentation has been reported with the help of a ureteroscopy or cystoscopy [16].

The MP system gives more stability, as the entire system is within the hands, providing excellent stability and manoeuvrability. The excess length of the shaft projecting out of the meatus, as with the ureteroscopy, is not encountered and the smallest available size to date is a clear advantage for urethral safety.

Deflux injection

Primary VUR is a common congenital urinary tract abnormality in children. There is considerable controversy regarding its management. Preservation of kidney function is the main goal of treatment, which necessitates identification of patients requiring early intervention. Surgical treatment, when chosen, encompasses endoscopic injection of bulking agents or ureteric re-implantation [17]. Owing to its minimally invasive nature, associated low morbidity and performance on an out-patient basis, the former is becoming increasingly popular as a treatment method.

Using cystoscopy, bulking materials are injected beneath the intramural part of the ureter in a submucosal location. The injected bulking agent elevates the ureteric orifice and the distal ureter, so that coaptation is increased. The lumen is thus narrowed, which prevents reflux of urine into the ureter while still allowing the urine's antegrade flow. With the availability of biodegradable substances, endoscopic subureteric injection of bulking agents has become an alternative to long-term antibiotic prophylaxis and surgical intervention in the treatment of VUR in children.

Deflux is indicated for treatment of children with VUR grades III–V. It is recommended to use the Deflux metal needle (3.7 F × 23 G tip × 350 mm) for safe and accurate administration of Deflux. Deflux can be injected with any common paediatric cystoscope with a minimum 4-F working channel. However, it seems intuitive that any cystoscope befitting the paediatric scenario and having a straight channel that accommodates the needle could work well. This led us to the realisation of the MP system, as it aptly fits this scenario.

In a meta-analysis [18], including 5527 patients and 8101 renal units, the reflux resolution rate (by ureter) after one treatment of grades I and II reflux was 78.5%, 72% for grade III, 63% for grade IV, and 51% for grade V. If the first injection was unsuccessful, the second treatment had a success rate of 68%, and the third treatment, 34%. The aggregate success rate with one or more injections was 85%.

PUV fulguration

The surgical treatment of PUV has transitioned from the open era to the present day minimally invasive approach of transurethral primary ablation of valvular tissue with modern fibre-optic endoscopic equipment [19]. To prevent stricture formation incision of the valves rather than aggressive ablation is recommended. The contemporary treatment methods include cold-knife incision, electrocautery incision, and laser fulguration. The latter has been performed using neodymium (Nd):YAG and recently even Ho:YAG laser [20].

However, to date the use of the MP armamentarium for the management of PUV has not been reported. The small 8-F sheath with the mounted three-way adapter incorporating the Ho laser 200- μ m fibre provides a viable alternative for managing these obstructing lesions of the narrow calibre paediatric male urethra. This forgoes the use of a paediatric cystoscope with a side channel.

In our present cases, we could successfully fulgurate the PUVs. Urethral injury with strictures have been reported in literature [21]; however, in our cases there was no injury to the urethra or sphincter and the patients were voiding well at the end of the 3-month

follow-up with improved uroflowmetry variables and absence of valves as seen on VCUG.

We have explored the possible use of a single armamentarium for varied indications in the present series. The small numbers and single institutional study are the limitations of the present study. Further follow-up of the treated patients and a multi-institutional study are required before we can advocate this as an alternate procedure for management.

Conclusion

Since its inception the MP armamentarium has been conventionally used for renal calculi. However, it can be strategically used for the management of various other urological conditions, both calculus and non-calculus. We found the MP armamentarium could be used for indications as yet untested with this modality, namely PUV fulgurations and Deflux injections. True to its name, it may be an 'All-Seeing Needle' in reality with much more to offer and harvest from.

Source of funding

None.

Conflicts of interest

None.

References

- [1] Türk C, Petřík A, Sarica K, Seitz C, Skolarikos A, Straub M, et al. EAU guidelines on interventional treatment for urolithiasis. *Eur Urol* 2016;**69**:475–82.
- [2] Bader MJ, Gratzke C, Seitz M, Sharma R, Stief CG, Desai M. The 'all-seeing needle': initial results of an optical puncture system confirming access in percutaneous nephrolithotomy. *Eur Urol* 2011;**59**:1054–9.
- [3] Sabnis RB, Ganesamoni R, Ganpule AP, Mishra S, Vyas J, Jagtap J, et al. Current role of microperc in the management of small renal calculi. *Indian J Urol* 2013;**29**:214–8.
- [4] Ganpule A, Chhabra JS, Kore V, Mishra S, Sabnis R, Desai M. Factors predicting outcomes of micropercutaneous nephrolithotomy: results from a large single-centre experience. *BJU Int* 2016;**117**:478–83.
- [5] Desai MR, Sharma R, Mishra S, Sabnis RB, Stief C, Bader M. Single-step percutaneous nephrolithotomy (microperc): the initial clinical report. *J Urol* 2011;**186**:140–5.
- [6] Ganesamoni R, Sabnis RB, Mishra S, Desai MR. Microperc for the management of renal calculi in pelvic ectopic kidneys. *Indian J Urol* 2013;**29**:257–9.
- [7] Ganpule AP, Mishra S, Desai MR. Percutaneous nephrolithotomy for pediatric urolithiasis. *Indian J Urol* 2010;**26**:549–54.
- [8] Herndon CD, Viamonte L, Joseph DB. Ureterscopy in children: is there a need for ureteral dilation and postoperative stenting? *J Pediatr Urol* 2006;**2**:290–3.
- [9] Kocaoglu C, Ozkan KU. The effectiveness of 4.5 Fulcrathin semi-rigid ureterscope in the management of ureteral stones in prepubertal children: is there a need for any ureteral dilatation? *Urology* 2014;**84**:202–5.

- [10] Atar M, Sancaktutar AA, Penbegul N, Soylemez H, Bodakci NK, Hatipoglu NK, et al. Comparison of a 4.5 F semi-rigid ureteroscope with a 7.5 F rigid ureteroscope in the treatment of ureteral stones in preschool-age children. *Urol Res* 2012;**40**:733–8.
- [11] Agrawal MS, Aron M, Goyal J, Elhence IP, Asopa HS. Percutaneous suprapubic cystolithotripsy for vesical calculi in children. *J Endourol* 1999;**13**:173–5.
- [12] Al-Marhoon MS, Sarhan OM, Awad BA, Helmy T, Ghali A, Dawaba MS. Comparison of endourological and open cystolithotomy in the management of bladder stones in children. *J Urol* 2009;**181**:2684–8.
- [13] Piskin MM, Guven S, Kilinc M, Arslan M, Goger E, Ozturk A. Preliminary, favorable experience with microperec in kidney and bladder stones. *J Endourol* 2012;**26**:1443–7.
- [14] Bodakci MN, Sancaktutar AA, Dağgulli M, Hatipoglu NK, Söylemez H, Penbegul N, et al. Micropercutaneous cystolithotomy in children: our experience with the transillumination technique. *J Endourol* 2014;**28**:693–8.
- [15] Walker BR, Hamilton BD. Urethral calculi managed with transurethral Holmium laser ablation. *J Pediatr Surg* 2001;**36**:16–7.
- [16] Bedir S, Kilciler M, Akay O, Erdemir F, Avci A, Ozgök Y. Endoscopic treatment of multiple prostatic calculi causing urinary retention. *Int J Urol* 2005;**12**:693–5.
- [17] Tekgül S, Riedmiller H, Hoebeke P, Kočvara R, Nijman RJ, Radmayr C, et al. EAU guidelines on vesicoureteral reflux in children. *Eur Urol* 2012;**62**:534–42.
- [18] Elder JS, Diaz M, Caldamone AA, Cendron M, Greenfield S, Hurwitz R, et al. Endoscopic therapy for vesicoureteral reflux: a meta-analysis, I: reflux resolution and urinary tract infection. *J Urol* 2006;**175**:716–22.
- [19] Mandal S, Goel A, Kumar M, Singh MK, Singh V, Sankhwar SN, et al. Use of holmium: YAG laser in posterior urethral valves: another method of fulguration. *J Pediatr Urol* 2013;**9**:1093–7.
- [20] Bhatnagar V, Agarwala S, Lal R, Mitra DK. Fulguration of posterior urethral valves using the Nd: YAG laser. *Pediatr Surg Int* 2000;**16**:69–71.
- [21] Sudarsanan B, Nasir AA, Puzhankara R, Kedari PM, Unnithan KR, Damisetti KR. Posterior urethral valves: a single center experience over 7 years. *Pediatr Surg Int* 2009;**25**:283–7.